

1975

The Histology of the Pineal Gland in *Odocoileus virginianus*

Terry Michael De Villiers

Eastern Illinois University

This research is a product of the graduate program in [Zoology](#) at Eastern Illinois University. [Find out more](#) about the program.

Recommended Citation

De Villiers, Terry Michael, "The Histology of the Pineal Gland in *Odocoileus virginianus*" (1975). *Masters Theses*. 3573.
<https://thekeep.eiu.edu/theses/3573>

This is brought to you for free and open access by the Student Theses & Publications at The Keep. It has been accepted for inclusion in Masters Theses by an authorized administrator of The Keep. For more information, please contact tabruns@eiu.edu.

PAPER CERTIFICATE #2

TO: Graduate Degree Candidates who have written formal theses.

SUBJECT: Permission to reproduce theses.

The University Library is receiving a number of requests from other institutions asking permission to reproduce dissertations for inclusion in their library holdings. Although no copyright laws are involved, we feel that professional courtesy demands that permission be obtained from the author before we allow theses to be copied.

Please sign one of the following statements:

Booth Library of Eastern Illinois University has my permission to lend my thesis to a reputable college or university for the purpose of copying it for inclusion in that institution's library or research holdings.

July 7, 1975

Date

Author

I respectfully request Booth Library of Eastern Illinois University not allow my thesis be reproduced because _____

Date

Author

pdm

The Histology of the Pineal

Gland in *Odocoileus virginianus*
(TITLE)

BY

Terry Michael De Villiers

THESIS

SUBMITTED IN PARTIAL FULFILLMENT OF THE REQUIREMENTS
FOR THE DEGREE OF

Master of Science

IN THE GRADUATE SCHOOL, EASTERN ILLINOIS UNIVERSITY
CHARLESTON, ILLINOIS

1975
YEAR

I HEREBY RECOMMEND THIS THESIS BE ACCEPTED AS FULFILLING
THIS PART OF THE GRADUATE DEGREE CITED ABOVE

7 - 7 - 75
DATE

ADVISER

7 July 1975
DATE

ABSTRACT

A total of 26 pineal glands from the white-tailed deer were histologically examined. Five different stains were utilized to determine various cell types present in pineal tissue. Connective tissue septa divide the pineal gland into incompletely separated lobules which are supplied by a very extensive vascular system. The pinealocyte is the most numerous cell in the gland and is most easily recognized by a prominent nucleus approximately 6-8 microns in diameter. The pinealocyte cytoplasm contains many minute granules. A distinct difference was noted in the histology of the oldest age deer pineal (age 7 years) when globular granules were observed throughout the gland. The granules appeared to be corpora acervuli common to pineal glands of ageing mammals.

ACKNOWLEDGEMENTS

I would like to extend to Dr. Eugene B. Krehbiel my respect and gratitude for aiding me in the development of this paper. Special thanks also go to Dr. Verne B. Kniskern for supplying me with materials essential to the completion of the research. Finally, I thank the Illinois Department of Conservation for the deer pineal glands.

TABLE OF CONTENTS

Abstract	i
Acknowledgements	ii
Table of Contents	iii
List of Figures	iv
Introduction and Literature Review	1
Methods and Materials	12
Observations	14
Discussion	22
Literature Cited	29

LIST OF FIGURES

Figure		Page
1	Incompletely separated lobules of pineal gland formed by connective tissue septa.	18
2	Connective tissue sheath surrounding pineal gland.	18
3	Pinealocyte cells of the deer.	18
4	Corpora acervuli of a seven year old male deer.	18
5	Average lengths of pineal gland in various age deer.	23

INTRODUCTION

The existence of the pineal gland has been known for over 2,000 years. Galen quoted earlier Greek writers that had observed the gland. According to Wurtman and Axelrod (1965) the pineal has been a mystery to man for many centuries and has led to much speculation with regard to its purpose. Perhaps the most interesting speculation was one held by Rene Descartes who felt the pineal gland housed the seat of the "rational soul." Descartes believed the eyes perceived events and relayed the message to the pineal where it would initiate proper muscle response.

Most recent studies of the pineal gland have been an attempt to elucidate the functional significance of the gland. Discovery of the potential hormone released by the pineal has resulted in the attempt to explain the glands function. This hormone, melatonin, was first isolated in 1958 (Lerner, 1958). Studies by many different workers on the pineal gland have provided much knowledge about melatonin and its function (Adams, Wan and Sohler, 1965; Barfuss and Ellis, 1971; Binkley, Weller and Klein, 1973; Quay, 1970; Wurtman and Axelrod, 1965 b; Reiter and Fraschini, 1969; and others).

Melatonin production has often been considered a function of environmental light (Fiske and Greep, 1959;

Fiske, Bryant and Putman, 1960; Kelly, 1962). The pineals of rats have been shown to be lighter weight after they were maintained in constant light than were those exposed to a normal day-night cycle. Anton-Tay and Wurtman (1968) showed that no light exaggerated the level of hamster hydroxyindole-O-methyl-transferase (HIOMT) enzyme which is needed for the production of melatonin. Reiter (1968) demonstrated that blinded golden hamsters will have involution of their reproductive organs within nine weeks due to increased melatonin levels. Therefore, the importance of the pineal and melatonin production in the hamster could be determined and recognized as an adaptive value. A decreasing photoperiod induces the pineal gland to stimulate gonadal involution and hibernation of the hamster. When sufficient daylight hours occur the pineal control is lifted and gonadal regeneration occurs at the appropriate time for reproduction of the species (Reiter, 1973 a; Reiter, 1973 b).

Likewise, rats exposed to reduced amounts of light showed an increase in N-acetyl-transferase of the pineal gland (Klein, Weller and Reiter, 1971). Binkley, Weller and Klein (1975) demonstrated the effect of pineal production of serotonin via increased N-acetyl-transferase activity to produce a 20-70 fold increase in circadian rhythm. Originally, Quay (1963) had found that serotonin content in the rat also undergoes marked circadian rhythm. Serotonin capacity drops rapidly at the

time melatonin activity begins to rise. When rats are maintained in constant light, the serotonin levels drop off, however, if the rats are kept in constant darkness the rhythm persists. This rhythm is unlike the action of the melatonin enzyme. When the pineal nerve innervation is destroyed both serotonin and HIOMT are reduced (Wurtman and Axelrod, 1965 a). One final consideration in the pineal glands sensitivity to environmental light is its relationship with the melanocyte stimulating hormone (MSH). Melatonin and MSH may be antagonistic since melatonin reduces the melanocyte cell perimeter and size while MSH has the opposite effect. Melatonin's effect on the melanocyte is fully reversed by the melanocyte stimulating hormone (Novales and Novales, 1965).

Controversy has not been settled as to the effect the pineal has on the pituitary gland. Kamberi, Mical and Porter (1970) provided evidence that LH releasing factor hormone can be effected by melatonin. Administration of melatonin via ventricular injection caused LH releasing factor to fall to undetectable levels in the blood until its return to normal levels after a two hour period. Kamberi, Mical and Porter (1971) later reported that melatonin injections intraventricularly also caused a 50% drop in FSH levels in the circulating blood. Serotonin also lowered FSH titres in this same experiment. These studies were later verified for all the gonadotropic hormones (Thiebolt, 1965). However, just the opposite

occurred in an experiment with rats when a three fold increase in levels of FSH were detected (Fraschini, 1969). One study indicates the pineal works independently of the hypophysis and the effect of the pineal are opposite that of the hypophysis (Glinsman, Vaughan, Vaughan and Klein, 1973). Mishkinsky, Nir, Lajtos and Sulman, (1966) reported the pineal does not exert any effect on the release of lactogenic hormones. A later experiment showed a persistent lowering of milk production after melatonin deposition (Shani, Knaggs and Tindal, 1971). The latter experiment has been considered invalid because of secondary implications of food intake. Clearly, much work is still needed in order to decide the definite role of pineal-pituitary interaction for control of the gonadotropins.

Limited studies of gross size of the pineal have been undertaken. Quay and Millar (1971) reported small rudimentary pineals in the elephant, several whales and Procavia. While small in whales, the seal and walrus have very large pineals. Pineals of 30 mm in length by 18 mm in width in the walrus and 20-30 mm in length by 10 mm in width in the seal have been reported (Cuellar and Tramezzani, 1969). The seal pineal gland weighed as much as one gram. Anderson (1965) described the 155-188 day-old cow fetus pineal as a tiny organ that is a miniature of the adult organ. Bloom and Fawcett (1962) reported the average human pineal gland measures 5 to 8 mm in length, and 3 to 5 mm at its greatest width. After careful study of hundreds of pineal

glands these average measurements for the human pineal have been confirmed (Scharenberg and Liss, 1965).

Major detail of the developmental aspects of the mammalian pineal gland have been well established by several authors (Jordan, 1911; Nelsen, 1953). A summary of embryological development of the pineal gland will be sufficient to help aid in the explanation of the histological features of the gland. The pineal gland begins embryonic development as an evagination from the roof of the diencephalon. The evagination is lined with ependymal cells which arise from spongioblasts derived from the neural epithelium, similar to the ventricles of the brain. The lumen of the pineal remains continuous with the third ventricle of the brain in most mammals as the pineal enlarges. When the pineal begins to form a sac-like structure the walls begin to form diverticulum which are continuous with the lumen of the pineal. The cells that line the diverticulum are pseudostratified and similar to the ependymal layer of the ventricles. Jordan (1911), and Anderson (1965) reported these pseudostratified cells form a rosette pattern which is especially well developed in the anterior part of the gland. As proliferation of these rosette arranged cells occur the minor lumina become blocked from the third ventricle. The pineal in some rodents such as the Norway rat are well separated from the diencephalon. Oksche (1965) warns against generalizations about the development of pineal glands because of variations found between

various species. Lower vertebrates have more complex pineal areas than the higher species of vertebrates. Complexity of the lower vertebrates is the result of the parapineals, dorsal sac and paraphysis found in these forms (Holmgren, 1965).

The pia mater supplies connective tissue which invades the pineal gland. This connective tissue carries capillaries which form a network throughout the gland. Division of the pineal gland in mammals has usually been determined by the position of its parts in regard to the diencephalon. The basal or proximal portion of the gland is that which lies closest to the diencephalon while the central (medulla) and distal portions are those which lie farther away from the diencephalon.

The neural ectoderm give rise to the specialized parenchymal cells, ependymal cells and glia cells which are mainly astrocytic in structure (Quay, 1965). Approximately 90% of the neural ectoderm cells are parenchymal cells in mammals and are referred to as pinealocytes (De Robertis and De Iraldi, 1961). The pinealocytes may form tubules, follicles or rosette patterns in some species or may be generally arranged in solid clusters, cords, or incomplete lobules in other species, depending on age (Quay, 1965). The mesodermal cells enter the pineal gland in conjunction with the vascular pathways. Along these vascular routes the connective tissue trabeculae are formed which separate the pineal into lobular areas. In some species the connective

tissue becomes especially thick in old age and this makes the lobules become quite distinct.

Arteries that supply the pineal run independently and along the periphery of the gland while the venules and capillaries are found throughout the gland. The venules usually occur just beneath the connective tissue trabeculae and drain into the large trunks bordering the pineal. The capillaries penetrating the rat pineal are enclosed by a basement membrane and contain endothelial cells (Milofsky, 1957). Wolfe (1965) and Machado (1966) later confirmed these reports using the electron microscope.

Bargmann (1943) reviewed and discussed the content and pattern of connective tissue fibers. Reticular or fine collagenous fiber networks are present in mammalian pineals to a far greater extent than found in brain vessels. The amount of connective tissue fiber has been noted to increase with age in man (Scharenberg and Liss, 1965). Elastic fibers have been rarely found in pineal tissue but have been found with aldehyde fuchsin stain in the walls of the larger blood vessels. (Quay and Kahn, 1963). Once again, these fibers appear to increase with age (Quay, 1965).

Striated muscle fibers have been located occasionally in mammalian pineals. Quay (1959) found striated muscle in three out of 1,200 rats he examined. The occurrence of striated muscle was later confirmed (Kappers, 1960). It was never fully understood why such a small percentage of pineals had striated muscle or why any muscle was

present.

The innervation of the mammalian pineal gland is still not fully understood. Efferent fibers run into the pineal from their origin in the central nervous system yet have not been shown to have any functional significance. Some of these fibers penetrate deep within the gland before turning 180 degrees to run back out the pineal (Kappers, 1965). Bargmann (1943) had shown a very limited amount of neurosecretory fibers in mammalian pineals but their significance is not yet understood. The mammalian pineal has no nerve fibers originating in the gland and running to the diencephalon, which is unlike the non-mammalian pineal complex (Van De Kamer, 1965). Therefore, the mammalian pineal is innervated by autonomic fibers. The gland has an orthosympathetic innervation coming from both cervical ganglia (De Iraldi, Zieher and De Robertis, 1965). The nerve fibers end freely about the capillaries or in association with the pinealocytes. The fact that the pineal differentiates from the brain, yet has no functional cerebral fibers, is quite unique.

The pinealocyte is the most numerous cell in the mammalian pineal. It is recognized by the large, sometimes invaginated nucleus and large nucleolus as well as its multiple cytoplasmic processes (Quay, 1965). Small chromatin granules are also characteristic in most mammalian pineals. Hortega (1932) described the cytoplasmic processes common

to the pinealocytes with the use of silver impregnation. Frequently, these processes are seen to extend within the perivascular connective tissue spaces close to the capillaries. The processes are variable with regard to number and structure for each cell and differ in various species.

Electron microscopy has confirmed the presence of mitochondria in the pinealocyte. An endoplasmic reticulum has also been observed (Anderson, 1965). The mitochondria were noted to extend all through the cells and even out into the cytoplasmic processes. Milofsky (1957) has shown the majority of the membranes of the endoplasmic reticulum are of the smooth variety. Vesicles of different sizes, content and shape have been described within the pinealocyte (Anderson, 1965; Wolfe, 1962; Milofsky, 1957). Much controversy has been raised over the function of these vesicles. Today, the excepted theory is that these vesicles produce indole amines.

Neuroglia cells, from the neuroectoderm, are present in all of the mammals studied to date. Fibrous astrocytes are the most numerous and have been found throughout the pineal. Quay (1965) has observed the astrocytes mainly interlobular and some intralobular. In addition, these astrocytes may have their processes end on capillaries, in the connective tissue spaces or freely about the pinealocytes. The astrocytes may contain mitochondria (Anderson, 1965). Oligodendroglia and protoplasmic astrocyte cells are much

fewer in number but have been observed (Hortega, 1932). Generally, the glia cells increase with age (Quay, 1965).

Other cell types have been found within the pineal gland. Izawa (1925), Quay (1956) and others have described plasma cells, mast cells, melanophores, fibroblasts, macrophages and lymphocytes. The reports are quite incomplete concerning these cells. Much work is still needed to determine the numbers and occurrences of these cells within the pineal gland.

The ageing process has a marked effect on the histology of the pineal gland. A well known change in ageing pineals is the formation of calcified "sand particles" or "brain sand" (corpora acervuli). In human pineals these particles vary in size and may become macroscopic. Scharenberg and Liss (1965) noted that these acervuli are often located around proliferated astroglia and connective tissue fibers and often contain concentric rings which suggests they have a vascular origin.

Several other factors may have an effect on pineal histology. A significant reduction in pineal weight was observed between day 10 and 20 of pregnancy in the white rat (Huang and Everitt, 1965). The reduction in weight apparently caused some unknown change in the histology of the gland. Reiss, Sideman and Plichta (1967) reported a change in cell density according to individual activity in lab rats. The slow runners showing little activity had a much greater

amount of cell density in their pineal glands than did the fastest runners. The high cell density was believed to have resulted in greater melatonin production and less activity.

The purpose of this study is to determine the general histologic pattern of the white-tailed deer (Odocoileus virginianus) pineal gland. The study will also show size and weight relationships between the pineal glands of various aged deer.

METHODS AND MATERIALS

The pineal glands used for this study were obtained from the white-tailed deer Odocoileus virginianus. The ages of the deer ranged from six months to seven years with the majority being the six months to one and a half years of age. The deer were obtained from three different sources. The first was from collections made at southern Illinois deer check stations in 1972 and 1973, the second from deer which died in transit from the Fort Massac State Park and the third source was from road kills. Twenty-six pineal glands were used with a total of twenty-five used for histological examination.

The deer were decapitated as soon as possible after death and a hack-saw was used to saw a transverse cut through the roof of the skull. Once the brain was exposed it was carefully removed and the pineal gland was severed from the brain with a scalpel. Excess connective tissue and blood were removed from the tissue so the pineal could be weighed and measured to the nearest millimeter. The pineals were measured in three directions which would represent their anatomical length, width, and height. The deer were aged by tooth replacement and wear and sexed by their genitalia. All information was recorded in a field notebook for future reference.

The pineal tissue was fixed in Bouin's or a mixture of acetic acid-formalin-and 80% ethyl alcohol. The standard methods for paraffin embedding, sectioning and mounting were followed (Humason, 1962). The tissue was cut into sections 10 microns in thickness.

Each pineal gland was stained with five different staining procedures. The periodic acid-Schiff reaction was used in order to determine the presence of any pineal tissue containing polysaccharides. The PAS alcoholic solution was utilized in staining (Humason, 1962). The Bodian method for silver impregnation was employed to show the glia elements present in pineal tissue (Humason, 1962). Astrocytes, nerve fibers and nerve tissue are highlighted with silver impregnation. Modifications by Halmi of the paraldehyde-Fuchsin staining method were utilized for determining nervous system granules and nucleoli as well as the general cellular staining. Heidenhain's iron haematoxylin was used as a staining method in order to demonstrate chromatin and mitotic apparatus. Mallory's triple stain was used to demonstrate the connective tissue and vascular components of the pineal gland.

Observation of the pineal tissue was made with a binocular microscope with magnification up to 1,000 times. Photographs of the pineal tissue were made with a 35 mm microscope-mounted camera. Dimensions of pineal cells and tissue were determined with the aid of ocular and stage micrometers.

OBSERVATIONS

The pineal gland of the white-tailed deer is basically spherical in shape with a slight enlargement of the part most distal from the brain. The gland was slightly longer than wide, but this difference never exceeded 2.5 mm with the average difference being only .95 mm in the 26 pineals measured. Length of the female pineal tended to be larger than the male gland in comparable aged deer. The female gland averaged 5.95 mm while the male averaged 5.35 mm (Table 1). Discarding the high and low extremes from the two groups resulted in a 5.75 mm average length for the female and 5.0 mm average for the male gland. The two largest glands collected were from $1\frac{1}{2}$ year old females. Pineal weight correlated closely to pineal size (i.e. the largest size had the greatest weight). Table 1 illustrates nearly a doubling of pineal weight between females of six months and $1\frac{1}{2}$ years. No apparent difference in size-weight relationship was observed comparing the male and female glands, especially when the high and low extremes were discarded.

The position of the deer pineal was found to be similar to domestic ungulates. It is attached to the dorsal portion of the diencephalon by the pineal peduncle. The

Table 1. Size and weight of pineal glands from various age white-tailed deer.

Number in sample	Sex	Age yrs.	Range	Length mm.	Range	Width mm.	Range	Height mm.	Range	Weight mg.
				\bar{X}		\bar{X}		\bar{X}		\bar{X}
10	F	$\frac{1}{2}$	4.5-6.0	5.5	3.5-5.0	4.4	2.0-5.0	4.3	30-111	51
4	F	$1\frac{1}{2}$	6.0-8.0	6.8	4.5-6.0	5.5	4.5-6.0	5.3	71-127	99
1	F	4	5.5	-	4.0	-	5.5	-	45	-
4	F	unk [*]	5.0-8.0	7.0	4.0-6.5	5.4	4.0-6.5	5.5	67-273	160
1	M	$\frac{1}{2}$	5.4	-	5.0	-	5.0	-	73	-
1	M	$1\frac{1}{2}$	5.5	-	4.0	-	4.0	-	38	-
1	M	7	4.2	-	4.0	-	4.0	-	38	-
3	M	unk [*]	4.0-7.0	5.7	4.0-7.0	5.7	4.5-6.0	5.2	53-126	80

* unk represents deer of unknown age.

peduncle was dorsally anchored by the habenular commissure and ventrally to the posterior commissure.

The pineal sheath or connective tissue capsule of the pineal gland was well developed and completely surrounded the gland measuring up to 250 microns in thickness. The trabeculae or connective tissue septa formed a branching type network throughout the pineal and divided the gland into incompletely separated lobules (Fig. 1). The incompletely separated lobules showed no distinct pattern. The connective tissue septa ranged from 200 micron in width in areas supporting vascular and nervous tissue to 10 microns in width in areas surrounded by pinealocytes. Observation of the connective tissue septa under low power (100 X) shows a network of coarse fibers and scattered, large, oval nuclei. Higher magnification (1,000 X) reveals fine, anastomosing fibers which surround the nuclei.

The vascular system of the pineal gland was well developed. Blood vessels were numerous in the connective tissue trabeculae and the pia sheath surrounding the pineal (Fig. 2). The largest arteries and veins were found in the cortex of the gland while only small venules and capillaries were found nearer the center of the gland. Many capillary systems could be observed throughout the entire gland.

The most numerous cell of the pineal gland of the deer

- Fig. 1. Incompletely separated lobules of pineal gland formed by connective tissue septa. (100 x)
- Fig. 2. Connective tissue sheath surrounding pineal of deer. Note the extensive blood supply. (100 x)
- Fig. 3. Pinealocyte cells of the deer. Note the distinct nucleus. (1,000 x)
- Fig. 4. Corpora acervuli of a seven year old male deer. (450 x)

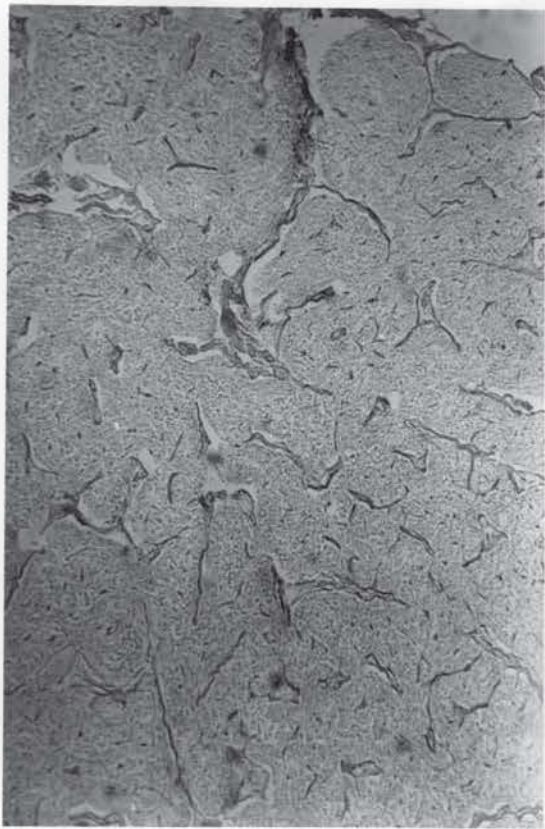


Fig. 1

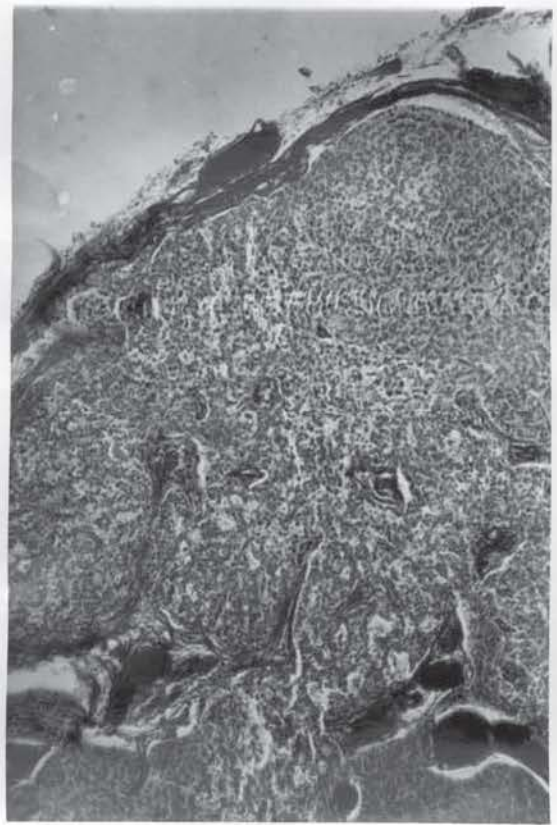

fig. 2

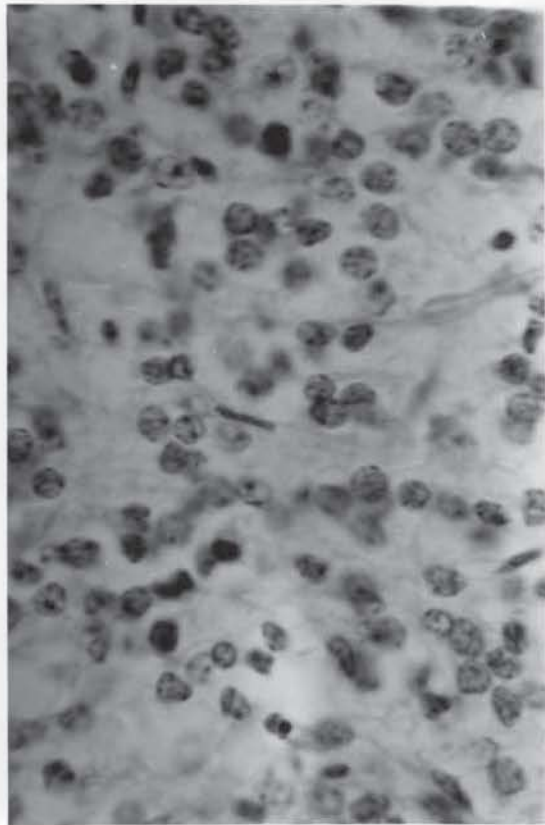


Fig. 3

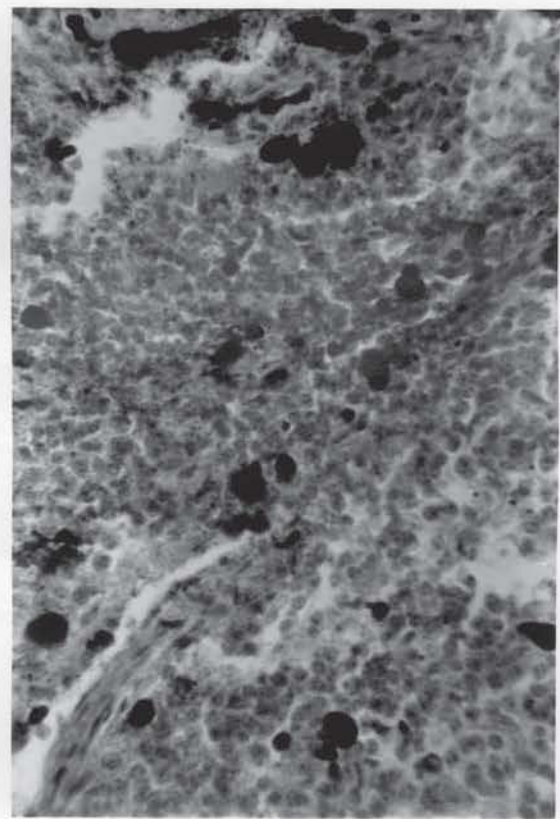


Fig. 4

was the pinealocyte. The pinealocytes were tightly packed throughout the pineal and were generally 20-25 microns in diameter. All pineal glands observed appeared to contain approximately the same number of pinealocytes per visual field. The pinealocytes were often found tightly lined around capillaries yet formed no distinct pattern similar to those reported by Quay (1965) for many animal species. Heidenhain's iron haematoxylin showed the pinealocyte has a distinct nucleus with a prominent nucleolus and chromatin material (Fig. 5). The nucleus was oval shaped and measured from 6-8 microns in diameter. An estimated one in 25 pinealocytes displayed a kidney shaped or inturned nucleus described by Quay (1965). The chromatin material of the nucleus appeared to have no definite size or pattern. No membrane covered nuclear body was observed. Nuclear components were also apparent with paraldehyde-fuchsin, Mallory's triple stain and PAS staining methods.

The pinealocyte cytoplasm was extremely resistant to coloration. Aldehyde-fuchsin stained the cytoplasm light green and demonstrated many minute particles within the cytoplasm. The minute granules in the cytoplasm would tend to suggest cellular organelles for metabolism (i.e. mitochondria) and protein synthesis already described with the aid of electron microscopy in other species (Anderson, 1965; Wolfe, 1962). A limited number of cytoplasmic elongations were observed following silver impregnation similar to those described by Quay (1965). The elongations of the cytoplasm were various lengths. No attempt to classify the pinealocytes according to their processes or granules was

undertaken in this study.

Differentiation of pineal neuroglia was best observed with silver impregnation staining. Fibrous astrocytes were observed in the deer pineal gland. Astrocytes were located throughout the gland with no definite relationship to connective tissue or blood vessels. Astrocytic nuclei were smaller than pinealocyte nuclei and could be distinguished by their darkly staining nuclear materials. Finger-like cell body projections of the astrocytes were extremely difficult to differentiate. Paraldehyde-Fuchsin stain showed thick bundles of unmyelinated nerve fibers in close association to the connective tissue septa. The nerve bundles appeared to follow the same route as the capillaries, branching out processes as they proceed.

Plasma cells, mast cells and macrophages were all noted within the deer pineal gland. These cells were located in close proximity to the vascular system. No striated muscle was found in any pineal. Apparent elastic fibers were observed in one pineal following PAS staining. The fibers were in the wall of a very large vein which appeared to enter the dorsal trunk.

The oldest deer, age seven, showed a marked difference in histology from any other deer. The middle aged deer showed no progressive steps toward the changes of the oldest deer. The oldest pineal gland possessed particles throughout the gland (Fig. 4). These particles appeared

to represent corpora acervuli common to pineals of ageing mammals. The acervuli were globular throughout the interlobular spaces but often elongate in the connective tissue septa. Gross examination of the oldest pineal gland revealed a blackened color instead of the usual cream color.

DISCUSSION

Enlargement of the deer pineal from 5.5 mm to 6.5 mm in the first year and a half of life was expected. The white-tailed deer demonstrates the majority of its overall body growth in the first year, so it could be expected that the pineal gland follow the same pattern. It appeared that reports by previous authors that believe gross pineal enlargement resulted from pinealocyte cell hypertrophy rather than an increase in cell number were accurate (Izawa, 1925; Quay and Levine, 1957). The pineal glands in this study appeared to all have approximately the same amount of cells. The female deer usually reaches sexual maturity within the first six months of life while the male deer does not express his sexual maturity until usually in the second breeding season at age one and a half years. Coupling maturity of the females and the small number of males sampled in this study could have resulted in the difference in size between male and female glands.

Larger samples of old deer will be necessary to determine any old age atrophy, if indeed any exists. Figure 5 shows the hypothetical atrophy of the older aged deer pineal glands. This figure tends to suggest that at age

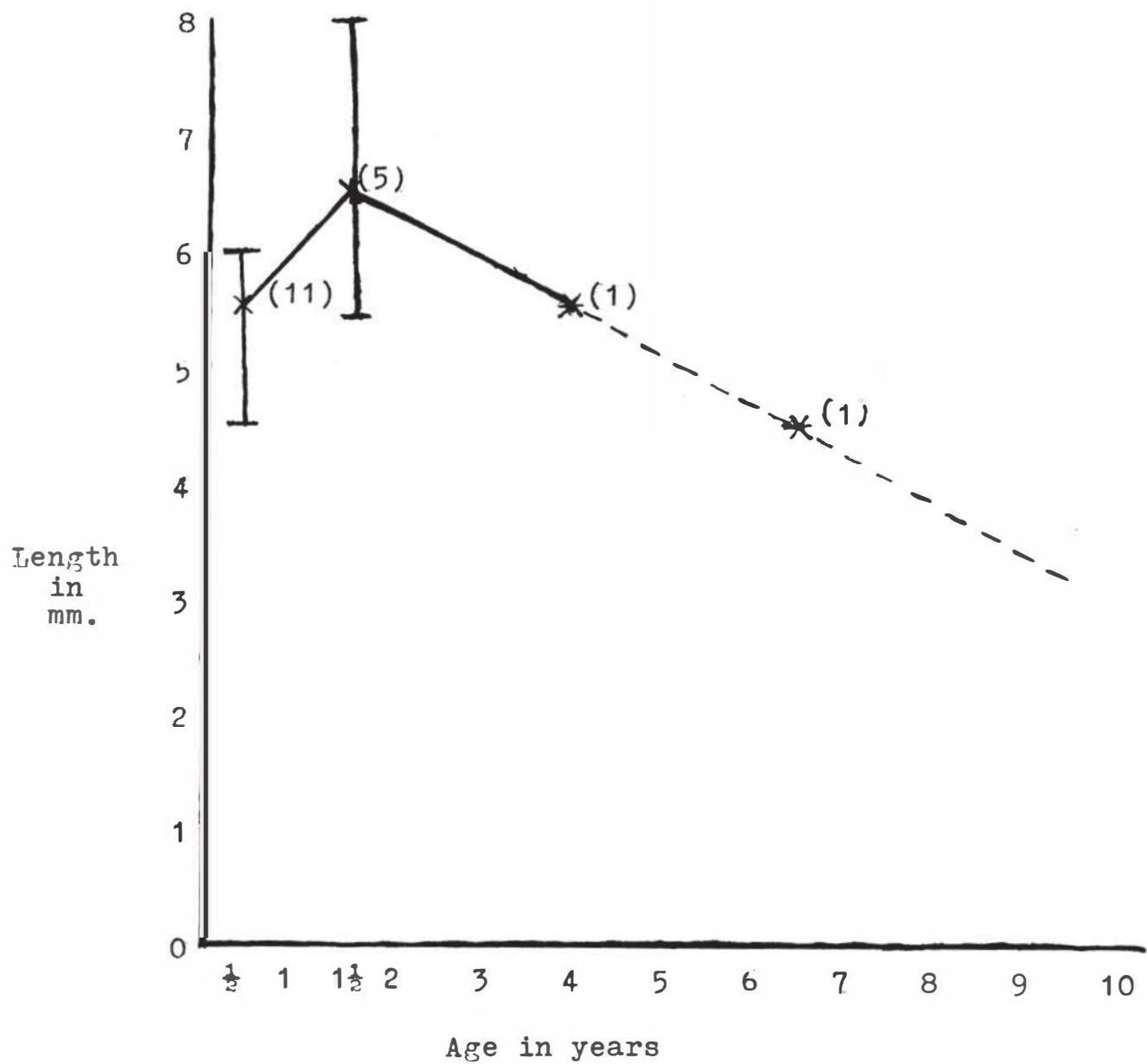


Fig. 5. Average length of pineal gland of white-tailed deer. Dotted line is hypothetical atrophy of pineal gland length. Note: Numbers in parentheses represent number in age group; vertical lines represent range.

one and a half years the pineal gland has reached its largest size and then begins to atrophy. Concluding atrophy of the pineal gland in ageing deer in this study has several drawbacks. The first is that an insufficient number of old deer were sampled. Secondly, the two old deer that were sampled were obtained from the state park pen. These penned deer were unable to obtain the plentiful food that wild deer enjoy and appeared undersized in all body respects. One final consideration which must be included is the time of year the pineal gland is collected. One would perhaps expect a smaller pineal gland during the breeding season when the majority of the glands for this study were collected (Quay, 1970). Increased pineal activity and perhaps larger pineals would be expected when the deer were not breeding due to the increased melatonin production. Many more pineal glands need to be measured to determine the actual growth pattern of the deer pineal.

At the present time no one has been able to determine the dynamics of blood flow through the pineal gland of any species. The lack of arteries flowing through the pineal tend to suggest a pressure type of blood flow from the cortex to the medulla of the gland. Quay (1958) established that the pineal gland in the rat has a limited capillary system as compared to other endocrine glands (i.e. pituitary) which suggested limited metabolic and

secretory activity in the pineal. Quantitative studies of the deer pineal and other endocrine glands and their capillary networks would be necessary to determine metabolic activity. The proximity with which the pinealocytes line the pineal capillary network must be considered in order to obtain accurate results. The close relationship the capillaries and pinealocytes maintain tend to suggest a less extensive capillary system is needed in the pineal as compared to other endocrine glands.

The connective tissue pattern and content of the deer pineal were quite similar to other reported species. (Quay, 1965). The observation of elastic fibers in the large vein was interesting. Very few cases of elastic fibers have ever been reported in the pineal gland. Quay (1965) states elastic fibers are extremely rare and occur primarily in the walls of the larger veins.

Unlike reports of pinealocytes from other species, the deer pinealocyte showed no distinct pattern of cellular arrangement except for its close association with the connective tissue and capillary systems.

Pinealocyte nuclear material has been a subject of controversy for over 60 years. So-called "Kernkugeln" pellets, the membrane covered secretory granules within the nucleus, had been repeatedly reported within a species, but their existence were later denied. Extensive study with the electron microscope has revealed two possible

explanations for Kernkugeln. Transversely sectioned cytoplasmic vesicles giving the impression of lying in the nucleus or enlarge nuclear material both give the impression of nuclear Kernkugeln (Kevorkian and Wessel, 1959). This study revealed no evidence of membrane covered Kernkugeln within the nucleus of any deer pineal. Perhaps further studies of the deer pineal would confirm that Kernkugeln pellets exist, especially if a large number of older aged deer were examined.

The cytoplasmic granules which were present in the pinealocyte were much too minute to classify in this study. Electron microscopy will be needed to determine the exact structures present in the deer pinealocyte cytoplasm. Speculation would suggest that mitochondria and vesicles which produce pineal indole amines are the majority of the cytoplasmic structures. The cytoplasmic processes of the pinealocyte were extremely difficult to locate. Hortega (1932) extensively described the cytoplasmic processes with the aid of silver impregnation. Compared to the human pinealocyte Hortega reported fewer processes in sheep and ox, so perhaps the number in deer is also reduced which could help account for the difficulty in locating them. Tissue preparation and technique used for silver impregnation may also have resulted in poor slide quality and therefore few visible processes.

Neuroglia elements were represented in rather

small quantity in the deer pineal. Observation of fibrous astrocytes were expected since they have been observed in all species thus far examined. The inability to find oligodendroglia cells in the deer was not alarming because only limited studies have reported this cell type. Inability to demonstrate these glia cells does not mean they were not present in the deer pineal. Once again, the silver impregnation staining method utilized for glia identification and varification may have resulted in limited and biased observation of pineal neuroglia. A much more comprehensive study is needed to determine the quantity and location of glia, especially fibrous astrocytes, in the deer. Perhaps this study would help clarify the controversy which now exists concerning the function of pineal neuroglia.

Histological changes which occurred in the oldest deer pineal follow the pattern of changes reported in most species. Calcification within the pinealocyte has been a well-known degenerative change in pineals of most species. The oldest pineal appeared black due to a very high amount of calcification which had taken place within the gland. The calcifications (corpora acervuli) were globular and amorphous but did not show concentric ring patterns reported in other species. Scharenberg and Liss (1965) attributed the concentric pattern of the acervuli to a vascular origin. If the acervuli have a vascular origin they show no apparent affinity to blood vessels.

It would be interesting to determine if pineal lymphatics played any role in the formation of corpora acervuli. Bargmann (1943) was the last person that attempted to determine pineal lymphatics. The acervuli which were elongate in the connective tissue septa have often been referred to as pineal concretions. No concretions were noted in neuroglia tissue.

LITERATURE CITED

- Adams, W.C., L. Wan and L. Sohler. 1965. Effects of melatonin on anterior pituitary luteinizing hormone. *J. Endocrinol.* 33:295-296.
- Anderson, E. 1965. The anatomy of Bovine and Ovine pineals. *J. Ultrastruct. Res. Suppl.* 8, 1-80.
- Anton-Tay, F. and R.J. Wurtman, 1968. Stimulation of hydroxy-indole-O-methyl-transferase activity in hamster pineal gland by blinding or continuous darkness. *Endocrinology* 82:1245-1246.
- Barfuss, D.W. and L.D. Ellis. 1971. Seasonal cycles in melatonin synthesis by the pineal gland as related to testicular function in the house sparrow. *Gen. Comp. Endocrinol.* 17:183-193.
- Bargmann, W. 1943. Die epiphysis cerebri. In *Handbuch der Mikroskopischen Anatomie des Menschen*. W.V. Mollendorff, Ed., Berlin, pp 309-502.
- Binkley, S., J.L. Weller and D.C. Klein. 1973. Production of induced pineal N-acetyl-transferase activity. *Fed. Proc.* 32:222.
- Bloom, W. and D.W. Fawcett. 1962. *A Textbook of Histology*. W.B. Saunders Co., Philadelphia. 720 pp.
- Cuello, A. and J. Tramezzani. 1969. The epiphysis cerebri of the Weddell seal: Its remarkable size and glandular pattern. *Gen. Comp. Endocrinol.* 12:154-164.
- De Iraldi, A.P., L.M. Zieher and E. De Robertis. 1965. Ultrastructure and pharmacological studies of nerve endings in the pineal gland. *Prog. Brain Res.* 10:389-422.
- De Robertis, E. and A.P. De Iraldi. 1961. Plurivesicular secretory processes and nerve endings in the pineal glands of the rat. *J. Biophys., Biochem., Cytol.* 10:361.
- Fiske, V.M. and R.O. Greep. 1959. Neurosecretory activity in rats under conditions of continuous light or darkness. *Endocrinology* 64:767-773.

- Fiske, V.M., G.K. Bryant and J. Putman. 1960. Effect of light on the weight of the pineal in the rat. *Endocrinology* 66:489-491.
- Fraschini, F. 1969. The pineal gland and control of LH and FSH secretion. *Prog. in Endocrinol.* ed. C. Gual, Amsterdam, Excerpta Medica, pp 637-644.
- Glinksman, W., G.M. Vaughan, M.K. Vaughan and D.C. Klein. 1973. Effects of pinealectomy on the thymus and on the hypothysectomy-induced regression of reproductive organs in rats. *Fed. Proc.* 32:223.
- Holmgren, L. 1965. On the ontogeny of the pineal and parapineal organs in Teleost fish. *Prog. Brain Res.* 10:172-182.
- Hortega, P.D. 1932. Pineal Gland. *In Cytology and Cellular Pathology of the Nervous System.* W. Penfield, Ed. New York. pp 637-703.
- Huang, C.Y. and A.V. Everitt. 1965. The effect of pregnancy on pineal weight in the rat. *J. Endocrinol.* 32:261-262.
- Humason, G.L. 1962. *Animal Tissue Techniques.* W.H. Freeman and Co., San Francisco, 468 pp.
- Izawa, Y. 1925. Studies on the pineal body; on the post-natal growth of the pineal body of the albino rat with observation on its histology. *J. Comp. Neurol.* 39:1-15.
- Jordan, H.E. 1911. Pineal body development. *Am. J. Anat.* 12:249-255.
- Kamberi, I.A., R.S. Mical and J.C. Porter. 1970. Effects of anterior pituitary perfusion and intraventricular injection of catecholamines and indoleamines on LH release. *Endocrinology* 87:1-12.
- Kamberi, I.A., R.S. Mical and J.C. Porter. 1971. Effects of melatonin and serotonin on the release of FSH and prolactin. *Endocrinology* 88:1288-1293.
- Kappers, J.A. 1960. The development, topographical relations and innervations of the epiphysis cerebri in the albino rat. *Z. Zellforsch* 52:163-215.
- Kappers, J.A. 1965. Survey of accessory pineal organs of vertebrates. *Prog. Brain Res.* 10:87-153.
- Kelly, D.E. 1962. Pineal organs: Photoreception, secretion and development. *Am. Sci.* 50:597.

- Kevorkian, J. and W. Wessel. 1959. So-called "nuclear pellets" (Kernkugeln) of pinealocytes. Am. Med. Assc. Arch. Pathol. 68:513-524.
- Klein, D.C., J.L. Weller and R.J. Reiter. 1971. Pineal N-acetyl-transferase activity in blinded and anosmic male rats. Endocrinology 89:1020-1023.
- Lerner, A.B. 1958. Isolation of melatonin, the pineal factor that lightens melanocytes. J. Am. Chem. Soc. 80:2587.
- Machado, A.B. 1966. Ultrastructure of the pineal body of the newborn rat. Anat. Rec. 154:381.
- Milofsky, A. 1957. The fine structure of the pineal in the rat, with special reference to parenchymal. Ant. Rec. 127:435-436.
- Mishkinsky, J., I. Nir, Z.K. Lajtos and F.G. Sulman. 1966. Mammary development in pinealectomized rats. J. Endocrinol. 36:215-216.
- Nelsen, O.E. 1953. Comparative Embryology of the Vertebrates. Mc Graw-Hill, New York. 414 pp.
- Novalles, R.R. and B.J. Novalles. 1965. Analysis of antagonisms between pineal melatonin which act on the Amphibian melanophore. Prog. Brain Res. 10:507-519.
- Oksche, A. 1965. Survey of the development and comparative morphology of the pineal organ. Prog. Brain Res. 10:3-29.
- Quay, W.B. 1956. Volumetric and cytologic variation in the pineal body of Peromyscus leucopus with respect to sex, captivity and day length. J. Morphol. 98:471-495.
- Quay, W.B. and B.E. Levine. 1957. Pineal growth and mitotic activity in the rat and effects of colchicine and sex hormones. Anat. Rec. 129:65-77.
- Quay, W.B. 1958. Pineal blood content and its experimental modification. Am. J. Physiol. 195:391-395.
- Quay, W.B. 1959. Striated muscle in the Mammalian pineal organ. Anat. Rec. 133:57-64.
- Quay, W.B. and R.H. Kahn. 1963. Pineal histology and cytochemistry in organ cultures. Cellule 63:247-257.

- Quay, W.B. 1963. Circadian rhythm in rat pineal serotonin and its modifications by the estrus cycle and photoperiod. *Gen. Comp. Endocrinol.* 3:473-479.
- Quay, W.B. 1965. Histological structure and cytology of the pineal organ in birds and mammals. *Prog. Brain Res.* 10:49-86.
- Quay, W.B. 1970. Endocrine effects of the Mammalian pineal. *Am. Zool.* 10:237-246.
- Quay, W.B. and R. Millar. 1971. Organization and histology of the pineal region in the hyrax Procavia capensis. *Am. J. Anat.* 130:377-392.
- Reiss, M., M.B. Sideman and E.S. Plichta. 1967. Spontaneous activity and pineal gland cell density. *J. Endocrinol.* 37:475-476.
- Reiter, R.J. 1968. Pineal function in long term blinded male and female golden hamsters. *Gen. Comp. Endocrinol.* 12:460-468.
- Reiter, R.J. and F. Fraschini. 1969. Endocrine aspects of the Mammalian pineal gland: A review. *Neuroendocrinology* 5:219-255.
- Reiter, R.J. 1973 a. Comparative physiology: Pineal gland. *Ann. Rev. Physiol.* 35:305-328.
- Reiter, R.J. 1973 b. Pineal control of a seasonal reproductive rhythm in male golden hamsters exposed to daylight and temperature. *Endocrinology* 92:423-430.
- Scharenberg, K. and L. Liss. 1965. The histologic structure of the human pineal body. *Prog. Brain Res.* 10:193-217.
- Shani, J., G.S. Knaggs and G.S. Tindal. 1971. The effect of noradrenaline, dopamine, 5-hydroxytryptamine and melatonin on milk yield and composition in the rabbit. *J. Endocrinol.* 50:543-544.
- Thieblot, L. 1965. Physiology of the pineal gland. *Prog. Brain Res.* 10:479-488.
- Van De Kamer, J.C. 1965. Histological structure and cytology of the pineal complex in Fishes, Amphibians and Reptiles. *Prog. Brain Res.* 10:30-48.
- Wolfe, D.E. 1965. Ultrastructure of rat epiphyseal cell. *Prog. Brain Res.* 10:332-369.

- Wurtman, R.J. and J. Axelrod. 1965 a. The pineal gland.
Sci. Am. 213:50-60.
- Wurtman, R.J. and J. Axelrod. 1965 b. The formation,
metabolism, and physiologic effects of melatonin in
mammals. Prog. Brain Res. 10:520-529.